

PRESENTING CLINICAL SIGNS

History: Grade IV/VI murmur. Previously diagnosed with stage B2 degenerative valve disease. Receiving furosemide 18.75 mg BID, enalapril 3.75 mg BID, and pimobendan 1.875 mg BID.

DATE

7/31/23

ECHOCARDIOGRAPHIC FINDINGS

2D, M-mode, and Doppler study.

PERFORMED BY:

Shari Reffi, CVT

INTERPRETED BY

Keith Blass, DVM,
MS, DACVIM
(Cardiology)

There is moderate to severe left atrial dilation. The mitral valve leaflets are thickened and exhibit mild systolic prolapse. A severe jet of eccentric mitral regurgitation is present. There is moderate to severe left ventricular dilation. Left ventricular systolic function is hyperdynamic. The aorta and aortic valve appear normal, though trace aortic insufficiency is present. Right atrial and right ventricular dimensions are normal. The tricuspid valve is normal. The pulmonary artery and pulmonic valve appear normal, though trace pulmonic insufficiency is present. No heartworms are visualized. No shunting lesions are visualized. No pericardial effusion or cardiac masses are seen.

LA - 45.0 mm
LVIDd - 44.7 mm
LVIDs - 24.1 mm
FS - 46%
RA - 18.0 mm
LVOT - 1.00 m/s
RVOT - 0.58 m/s

PATIENT

Jellybean Bhartiya

SPECIES

Canine

BREED

Coton De Tulear

ASSESSMENT/RECOMMENDATIONS

Degenerative mitral valve disease

This examination demonstrates mild progression of Jellybean's mitral valve disease over the past 16 months, as he now has moderate to severe dilation of both his left atrium and left ventricle. Given this, Jellybean is at high risk for the development of clinical signs secondary to his disease, such as coughing, exercise intolerance, syncope, and labored breathing, therefore, careful monitoring for these is recommended.

Jellybean's current cardiac medications are appropriate, and no change in therapy is recommended if he is currently asymptomatic.

SEX

A recheck echocardiogram is recommended in 6-9 months. Thoracic radiographs are recommended if Jellybean experiences respiratory clinical signs.

MN

AGE

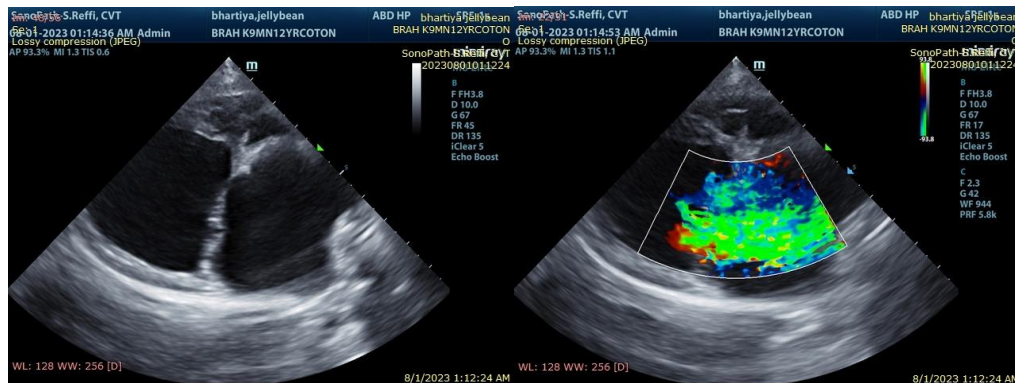
12 y

WEIGHT

15.3 lb

HOSPITAL NAME

Basking Ridge AH



REFERRING VET

Dr. Hollo

The information and recommendations provided are based on the images presented by the



referring veterinarian. No evaluation can be communicated regarding pathology that was not visible in the image/video clips provided.

DATE

7/31/23

Thank you for this referral. If the clinical or image interpretation does not parallel your findings or if I can be of any further assistance please contact me.

PERFORMED BY:

Keith Blass, DVM, MS, DACVIM (Cardiology)

KeithBlass@gmail.com

631-804-5754

Shari Reffi, CVT

INTERPRETED BY

Keith Blass, DVM,
MS, DACVIM
(Cardiology)

PATIENT

Jellybean Bhartiya

SPECIES

Canine

BREED

Coton De Tulear

SEX

MN

AGE

12 y

WEIGHT

15.3 lb

HOSPITAL NAME

Basking Ridge AH

REFERRING VET

Dr. Hollo